

Long-term stability of anterior open bite closure corrected by surgical-orthodontic treatment

Marjut Teittinen*, Veikko Tuovinen*, Leena Tammela*, Marc Schätzle** and Timo Peltomäki***

*Department of Oral and Maxillofacial Surgery, Central Hospital of Central Finland, Jyväskylä, Finland, **Clinic for Orthodontics and Paediatric Dentistry, Centre for Dental and Oral Medicine and Cranio-Maxillofacial Surgery, University of Zurich, Switzerland and ***Dental and Oral Diseases Outpatient Clinic, Department of Eye, Ear, and Oral Diseases, Tampere University Hospital and Department of Otolaryngology, Tampere University, Tampere, Finland

Correspondence to: Dr Timo Peltomäki, Dental and Oral Diseases Outpatient Clinic, Department of Eye, Ear and Oral Diseases, Tampere University Hospital and Department of Otolaryngology, Tampere University, PO Box 2000, FI-33521 Tampere, Finland. E-mail: timo.peltomaki@pshp.fi

SUMMARY In adults, superior repositioning of posterior maxilla with or without mandibular surgery has become the treatment method of choice to close anterior open bite. Study aim was to examine the long-term stability of anterior open bite closure by superior repositioning of maxilla or by combining maxillary impaction with mandibular surgery.

The sample comprised 24 patients who underwent anterior open bite closure by superior repositioning of maxilla (maxillary group, $n = 12$, mean age 29.3 years) or by maxillary impaction and mandibular osteotomy (bimaxillary group, $n = 12$, mean age 30.8 years). Lateral cephalograms were studied prior to surgery (T1), the first post-operative day (T2) and in the long term (T3, maxillary group mean 3.5 years; bimaxillary group mean 2.0 years). Paired and two-sample *t*-tests were used to assess differences within and between the groups.

The vertical incisal bite relations were -2.6 and -2.2 mm at T1; 1.23 and 0.98 mm at T2; and 1.85 and 0.73 mm at T3 in the maxillary and bimaxillary groups. At T3, all subjects had positive overbite in the maxillary group, but open bite recurred in three subjects with bimaxillary surgery. For both groups, the maxilla relapsed vertically. Significant changes in sagittal and vertical positions of the mandible occurred in both groups. In the bimaxillary group, the changes were larger and statistically significant.

In general, the maxilla seems to relapse moderately vertically and the mandible both vertically and sagittally, particularly when both jaws were operated on. Overbite seems to be more stable when only the maxilla has been operated on.

Introduction

Treatment of anterior open bite is a great challenge in orthodontics. Commonly, anterior open bite is characterised by over-eruption of the upper posterior teeth and posterior rotation of the mandible (Sassouni and Nanda, 1964; Subtelny and Sakuda, 1964; Ellis *et al.*, 1985). Attempts to control maxillary development and prevent eruption of the posterior teeth during growth are often frustrated by late adolescent growth changes (Proffit *et al.*, 2000). Relapse has been reported in 20–44% of conventionally treated patients in the long term (Lopez-Gavito *et al.*, 1985; Huang, 2002; Janson *et al.*, 2003; Remmers *et al.*, 2008). Until the present era of various bone-borne temporary anchorage devices (TADs), intrusion of upper molars has been very difficult to accomplish, and extrusion of anterior teeth has instead been achieved. While the reported short-term results of TADs seem to be encouraging (Umemori *et al.*, 1999; Sherwood *et al.*, 2002; Park *et al.*, 2005; Kravitz and Kusnoto, 2007; Xun *et al.*, 2007), no long-term studies of the stability are available.

In non-growing patients, there are two options remain for correction of anterior open bite: extrusion of anterior teeth or orthognathic surgery (Chang and Moon, 1999; Proffit *et al.*, 2000). Superior repositioning of the posterior maxilla with or without mandibular surgery has become the treatment method of choice in adult patients to close an anterior open bite to ensure facial harmony and functional occlusion. Several reports have described the initial and short-term results, which are fairly stable. Long-term studies over 1 year, however, indicate some relapse attributed to various factors (Bailey *et al.*, 1994; Hoppenreijns *et al.*, 1997; Fischer *et al.*, 2000; Proffit *et al.*, 2000; Swinnen *et al.*, 2001; Iannetti *et al.*, 2007). Confounding factors in the long-term studies, including patients with vertical excess but not necessarily an anterior open bite, different maxillary and mandibular osteotomies, different fixation methods (wire, rigid internal, or maxillomandibular fixation), and surgeries performed by different surgeons, have not been accounted for, and patients have often been pooled into one group. Information about long-term stability

beyond 1 year is needed because changes have been shown to occur up to 5 years after surgery (Proffit *et al.*, 1996, 2007).

The aim of this study was to examine long-term stability of anterior open bite closure achieved by one of two surgical-orthodontic methods: superior repositioning of the posterior maxilla or combining maxillary impaction with mandibular surgery.

Subjects and methods

The subjects of the study were 24 consecutive healthy adult patients who had anterior open bite closure treated using a surgical-orthodontic method: superior repositioning of the posterior maxilla by Le Fort I osteotomy followed by autorotation of the mandible (maxillary group) or by superior repositioning of the posterior maxilla by Le Fort I osteotomy combined with mandibular osteotomy (bimaxillary group). Both groups consisted of 12 patients (maxillary group: mean age 29.3 years, range 17–31 years; bimaxillary group: mean age 30.8 years, range 18–50 years).

Two-jaw surgery was planned and performed if mandibular autorotation would not lead to an acceptable maxillomandibular relationship and overjet. All surgeries were performed by the same surgeon (VT). The maxilla was posteriorly impacted in one piece (clockwise rotation) and, in most patients, was also advanced. The mandible was operated on using bilateral sagittal split osteotomy. Rigid internal fixation (RIF) was used in all patients to stabilize the osteotomies; none of the patients underwent maxillomandibular fixation. All patients had pre- and post-operative orthodontic treatment with the 0.018-slot straight wire technique. An attempt was always made to avoid closing the open bite by the presurgical orthodontic treatment.

Lateral cephalograms were obtained at three time points: prior to operation (T1), the first post-operative day (T2), and in the long term after orthognathic surgery (T3, maxillary group mean 3.5 years, range 1.7–4.7 years; bimaxillary group mean 2.0 years, range 1.0–3.7 years). The cephalograms were digitized and analysed with Facad® software (Ilexis AB, Linköping, Sweden). The SNA, SNB, and ANB angles were used to study the changes in the sagittal direction, and the angles between the sella–nasion and maxillary lines (SN–max), between the SN and the mandibular line (SN–mand), and between the maxillary and mandibular lines (max–mand) were used to study vertical changes. The position of the upper first molar was measured using the distance from the mesial cusp tip perpendicularly to the SN or maxillary line. The lower first molar position was measured from the mesial cusp tip perpendicularly to the mandibular line. The positions of the upper and lower incisors were measured from the incisal edge along the long axis to the maxillary and mandibular lines, respectively.

Overbite/open bite was measured on the cephalograms as the vertical distance between the incisal edges of the upper and lower incisors projected perpendicularly to the nasion–menton line. The measurements (including landmark identification) were repeated after 2 weeks by the same orthodontist (MT), and the mean of the measurements was used in the statistical analyses.

Statistical analysis was performed with the SPSS 15.01 for Windows (SPSS Inc., Chicago, Illinois, USA). Focusing mainly on the skeletal and dental changes over time (T2–T3), paired and two-sample *t*-tests were used to study the possible differences within the groups and between the groups. The level of significance was set at $\alpha = 0.05$.

Results

Statistical analysis showed that the two groups were not statistically different initially (Table 1). On average, overbite was -2.6 and -2.2 mm in the maxillary and bimaxillary groups, respectively. Patients in the bimaxillary group tended to have a greater sagittal mandibular discrepancy (SNB) and greater mandibular plane angle (SN–mand).

The main outcome variable of interest of the study, i.e. overbite, showed different changes between the study groups immediately after surgery and during the follow-up period. At the operation (T2), the overbite was changed in the maxillary group slightly more than in the bimaxillary group, ending with values of 1.23 and 0.98 mm, respectively. During the follow-up period, the bite seemed, on average, to deepen in the maxillary group, but it opened slightly in the bimaxillary group. In the long-term follow-up (T3), overbite was 1.85 mm in the maxillary group and 0.73 mm in the bimaxillary group. Different changes in the overbite were not statistically significant (Table 2).

In Figure 1a, the overbite changes of the maxillary group between time points T2 and T3 are depicted. After the maxillary impaction, four patients showed an overbite of less than 1 mm, with increase over time (T3). Three of eight patients showing an overbite of more than 1 mm immediately after the surgery had a bite-opening tendency but retained a positive overbite. In the bimaxillary group, 5 of 12 patients showed an overbite of less than 1 mm at T2 (Figure 1b). At T3, this proportion increased. Finally, open bite recurred in three patients in the bimaxillary group at T3.

For both groups, the maxilla was observed to relapse vertically (anticlockwise rotation), i.e. the SN–max angle decreased. The change was statistically significant only for the maxillary group ($P = 0.046$); however, there was no difference between the groups. A statistically significant change in the sagittal position of the mandible (SNB) was observed in both groups. The difference between the groups was also significant ($P = 0.004$); the bimaxillary group had a larger change. Additionally, the mandible showed statistically significant vertical change (SN–mand) in the

Table 1 Mean values at different time points (T1, T2, and T3) for the maxillary and bimaxillary groups. SD, standard deviation.

	Maxillary group			Bimaxillary group		
	T1	T2	T3	T1	T2	T3
	Mean ± SD	Mean ± SD	Mean ± SD	Mean ± SD	Mean ± SD	Mean ± SD
SNA	81.78 ± 2.93	85.18 ± 2.94	84.71 ± 2.93	82.10 ± 3.55	83.41 ± 5.23	83.00 ± 4.67
SNB	80.30 ± 3.57	82.26 ± 3.64	81.24 ± 3.67	77.40 ± 7.38	81.39 ± 5.45	78.25 ± 6.33
ANB	1.52 ± 3.37	2.92 ± 2.11	3.45 ± 1.98	4.65 ± 5.82	2.02 ± 3.46	4.74 ± 3.91
SN-max	5.15 ± 2.16	9.59 ± 3.23	7.45 ± 3.08	5.49 ± 3.91	8.27 ± 3.91	7.06 ± 4.14
SN-mand	38.15 ± 6.33	34.17 ± 7.30	35.84 ± 5.95	42.08 ± 9.27	37.48 ± 8.47	41.25 ± 10.37
Max-Mand	32.98 ± 6.57	26.17 ± 5.78	28.38 ± 5.80	36.57 ± 9.40	29.24 ± 7.10	34.20 ± 8.78
SN-U6	75.11 ± 8.18	72.33 ± 8.31	71.88 ± 8.26	71.15 ± 2.98	67.83 ± 2.80	67.98 ± 3.12
Max-U6	25.66 ± 3.98	25.27 ± 4.15	24.50 ± 3.93	24.03 ± 2.00	23.37 ± 1.80	23.13 ± 1.80
Mand-L6	32.23 ± 3.44	32.45 ± 3.70	31.84 ± 4.03	32.33 ± 3.72	31.48 ± 2.94	31.67 ± 3.69
Max-U1	33.40 ± 4.17	32.80 ± 4.36	33.19 ± 4.44	32.63 ± 2.58	31.97 ± 2.50	32.41 ± 2.15
Mand-L1	43.25 ± 4.74	43.19 ± 4.75	43.31 ± 5.29	42.22 ± 4.39	41.52 ± 3.92	41.90 ± 3.99
Overbite	-2.55 ± 1.41	1.23 ± 1.05	1.85 ± 0.93	-2.19 ± 1.44	0.98 ± 1.53	0.73 ± 0.93

Table 2 Mean changes, standard deviations, and *P* values of changes within and between the groups in the long term (T3–T2). SD, standard deviation.

	Maxillary group			Bimaxillary group			
	Mean	SD	<i>P</i> value	Mean	SD	<i>P</i> value	<i>P</i> value between groups
SNA	-0.47	1.41	0.276	-0.41	2.12	0.515	0.942
SNB	-1.02	1.33	0.022*	-3.15	1.85	0.001***	0.004**
ANB	0.53	0.93	0.074	2.65	0.56	0.001***	0.003**
SN-max	-2.14	3.31	0.046*	-1.38	2.34	0.066	0.521
SN-mand	0.84	2.17	0.206	3.60	2.68	0.001***	0.011*
Max-Mand	2.21	2.53	0.012*	4.63	3.02	0.001***	0.045*
SN-U6	-0.45	2.96	0.609	0.14	1.90	0.796	0.56
Max-U6	-0.77	1.42	0.088	-0.24	0.86	0.359	0.279
Mand-L6	-0.61	1.54	0.197	0.18	1.66	0.709	0.237
Max-U1	0.40	1.24	0.293	0.44	1.01	0.159	0.922
Mand-L1	0.12	2.38	0.864	0.38	0.75	0.111	0.728
Overbite	0.59	1.40	0.175	-0.25	1.33	0.529	0.148

P* < 0.05; *P* < 0.01; ****P* < 0.001

bimaxillary group as the result of a clockwise rotation and a bite-opening tendency (*P* = 0.001 within the group and *P* = 0.01 between the groups). Dental changes did not reach statistical significance, but the upper and lower incisors tended to elongate in both groups in the long term (Table 2).

Discussion

The present study aimed to assess the long-term stability of anterior open bite closure with superior repositioning of the posterior maxilla either alone or in combination with mandibular surgery. To reduce confounding factors, only patients operated upon by the same surgeon using the same surgical technique were included. Because RIF is known to

increase the stability of orthognathic surgery (Forsell *et al.*, 1992; Hoppenreijns *et al.*, 1997; Proffit *et al.*, 2007), only patients with RIF were studied. Post-operative changes up to 1 year have been considered to be surgery related, but once healing is complete and orthodontic appliances have been removed; changes thereafter can be related to long-term adaptation and, in some patients, to post-treatment growth (Proffit *et al.*, 2007). Due to the fact that the swelling caused by the surgery and hard tissue correlations were the strongest immediately after surgery and weaker later, patients beyond 1 year post-surgery were included to assess long-term stability (Dolce *et al.*, 2003). The limitations of the study include the small sample size and the retrospective design, which preclude firm conclusions.

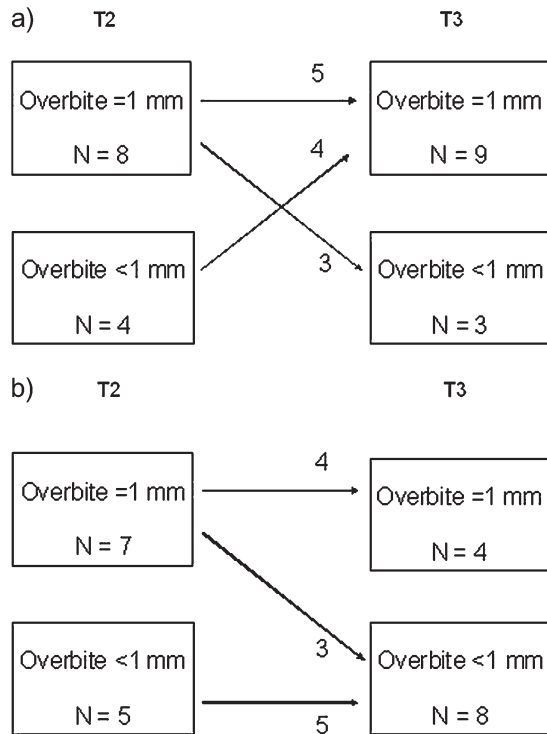


Figure 1 Course of overbite in the maxillary group (a) and course of overbite in the bimaxillary group (b).

It has been suggested that the stability should be reported as a percentage of patients with a significant post-treatment change for the given treatment (Proffit and Phillips, 2003). Accordingly, ‘highly stable’ denotes the condition when less than 10% of the patients have a significant post-treatment change, and ‘stable’ denotes the condition when less than 20% of the patients have a significant post-treatment change and almost none have major post-treatment changes. Another way of interpreting stability has been to set metric and angular cut-off values. Changes greater than 2 mm or greater than 2 degrees are considered clinically significant, and changes greater than 4 mm or greater than 4 degrees are considered highly clinically significant (Proffit *et al.*, 2000). In a recent publication (Proffit *et al.*, 2007), changes of less than 2 mm were considered to fall within the range of method error in the cephalometric analysis and were therefore clinically insignificant. Changes 2–4 mm are potentially clinically significant, and changes greater than 4 mm are often beyond the range of orthodontic compensation and regarded as clinically highly significant. Concerning the main topic of the present study, i.e. overbite, these definitions of stability and their clinical significance are probably not applicable. In terms of overbite, the condition is probably clinically significant if overbite is positive in the long term regardless of the amount of relapse/change. Furthermore, the amount of overbite may also be significant.

No consensus exists concerning the concept of an ideal functional occlusion (Clark and Evans, 2001). Despite insufficient scientific proof, posterior contacts on protrusion are commonly considered to be unfavourable interferences, and in an ideal functional occlusion, overbite should be large enough to allow disclusion of posterior teeth on mandibular protrusion (Roth, 1981; Kirveskari, 1981). Patients with anterior open bite have been found to have significantly increased odds for temporomandibular disorders (Pullinger *et al.*, 1993). Specifically, Milosevic and Samuels (1998, 2000) found that patients with overbite less or equal to 2.4 mm had significantly more protrusive posterior contacts than those with overbite greater than 2.4 mm. These authors concluded that ‘overbite of not less than 2 mm should be considered an orthodontic treatment goal’. When achievement of at least 1.0 mm of overbite is set as minimum in the present study, it is evident that great individual variation and differences exist between the groups. At T2, 8/12 patients of the maxillary group belonged to the ideal pool (overbite greater than or equal to 1 mm). Out of these, 5 remained in this ideal pool, and the 4/12 patients who had suboptimal overbite (less than 1 mm) at T2 improved and shifted into the ideal pool at T3. In the bimaxillary group, 7/12 patients at T2 were in the ideal pool, but 3 of these shifted into the suboptimal pool at T3. Furthermore, all 5/12 patients in the bimaxillary group with overbite less than 1 mm at T2 remained in their initial pool (Figure 1). Our finding of a tendency for the overbite to increase gradually following maxillary impaction agrees with the results of a study by Espeland *et al.* (2008).

All patients in the maxillary group had positive overbite at T3, but open bite recurred in three patients in the bimaxillary group in the course of the follow-up. A closer look at these individuals revealed that they were all initially Class II patients with considerable sagittal discrepancy with a mean ANB angle of 8.5 degrees (whole group mean, 4.6 degrees) and vertical excess (SN–mand 47.9 degrees; whole group mean, 42.1 degrees). Our finding is well in line with the conclusions of Proffit *et al.* (2007), who stated that ‘a surprisingly large number of patients experience skeletal changes from one to five years post-surgery, and in that time frame clinically relevant (greater than 2 mm) changes are more likely in Class II/long face patients than in Class III patients’. Long-face patients appear to be at a higher risk of long-term skeletal relapse, probably for at least two reasons. These patients usually require a large amount of mandibular advancement, which is known to be a risk factor in the absence of adequate muscular adaptation (Reynolds *et al.*, 1988; Hoppenreijts *et al.*, 1998). In addition, patients with preoperative high mandibular plane angle have an elevated risk for unfavourable condylar remodelling or condylar resorption with bite opening after surgical-orthodontic treatment (Hoppenreijts *et al.*, 1998; Arpornmaeklong and Heggie, 2000; Eggenesperger *et al.*, 2006).

As indicated above, mandibular changes after open bite closure by orthognathic surgery may negatively impact the long-term stability of the closure. While the maxilla showed similar minor changes in both groups, confirming previous findings (Proffit *et al.*, 2000; Ding *et al.*, 2007; Iannetti *et al.*, 2007; Espeland *et al.*, 2008), the mandible considerably rotated posteriorly, with increases in the SNB and mandibular plane angles. Adaptive changes in the dentition have been found to occur as the result of partial compensation for unfavourable skeletal changes (Ding *et al.*, 2007; Proffit *et al.*, 2007; Espeland *et al.*, 2008). In the present study, no statistically significant dental changes were noted. In both groups, however, approximately 0.6 mm total elongation of the upper and lower incisors was found, which may be clinically significant and sufficient to compensate for the relapse of the maxillary position in the maxillary group but to a lesser extent in the bimaxillary group, which experienced considerable long-term mandibular change.

The results of the present study confirm those of previous studies on the high stability of superior repositioning of the maxilla using one-piece Le Fort I osteotomy. The long-term stability of patients with maxillary impaction to close anterior open bite is generally good. On the other hand, it seems that the compromised mandibular stability is the most influential factor that negatively affects the long-term stability of anterior open closure corrected either by operating only on the maxilla or by operating on both jaws.

Conclusions

Within the limitations of the small sample size and the retrospective study design, we conclude the following:

- The maxilla seems to relapse moderately vertically, and the mandible seems to relapse both vertically and sagittally, particularly if both jaws have been operated upon.
- Overbite seems to be more stable, or may even increase, when only the maxilla has been operated upon.
- The mandible seems to be the 'weak link', i.e. compromised mandibular stability is an influential factor to the long-term stability of anterior open closure corrected either by operating only on the maxilla or by operating on both jaws.
- Patients with Class II open bite with sagittal discrepancy and vertical excess have a high risk for relapse.

This retrospective study points to several risk indicators. To confirm the significance of these risk factors, they must be re-evaluated in well-designed prospective studies with sufficient sample sizes.

References

Arpornmaeklong P, Heggie A A 2000 Anterior open-bite malocclusion: stability of maxillary repositioning using rigid internal fixation. *Australian Orthodontic Journal* 16: 69–81

- Bailey L J, Phillips C, Proffit W R, Turvey T A 1994 Stability following superior repositioning of the maxilla by Le Fort I osteotomy: five-year follow-up. *International Journal of Adult Orthodontics and Orthognathic Surgery* 9: 163–173
- Chang Y I, Moon S C 1999 Cephalometric evaluation of anterior open bite treatment. *American Journal of Orthodontics and Dentofacial Orthopedics* 115: 29–38
- Clark J R, Evans R D 2001 Functional occlusion: I. A review. *Journal of Orthodontics* 28: 76–81
- Ding Y, Xu T M, Lohrmann B, Gellrich N C, Schweska-Polly R 2007 Stability following combined orthodontic-surgical treatment for skeletal anterior open bite—a cephalometric 15-year follow-up study. *Journal of Orofacial Orthopedics* 68: 245–256
- Dolce C, Hatch J P, Van Sickels J E, Rugh J D 2003 Five-year outcome and predictability of soft tissue profiles when wire or rigid fixation is used in mandibular advancement surgery. *American Journal of Orthodontics and Dentofacial Orthopedics* 124: 249–256
- Eggensperger N, Smolka K, Luder J, Iizuka T 2006 Short- and long-term skeletal relapse after mandibular advancement surgery. *International Journal of Oral and Maxillofacial Surgery* 35: 36–42
- Ellis E 3rd, McNamara J A Jr., Lawrence T M 1985 Components of adult Class II open-bite malocclusion. *Journal of Oral and Maxillofacial Surgery* 43: 92–105
- Espeland L, Dowling P A, Mobarak K A, Stenvik A 2008 Three-year stability of open-bite correction by 1-piece maxillary osteotomy. *American Journal of Orthodontics and Dentofacial Orthopedics* 134: 60–66
- Fischer K, von Konow L, Brattström V 2000 Open bite: stability after bimaxillary surgery -2-year treatment outcomes in 58 patients. *European Journal of Orthodontics* 22: 711–718
- Forssell K, Turvey T A, Phillips C, Proffit W R 1992 Superior repositioning of the maxilla combined with mandibular advancement: mandibular RIF improves stability. *American Journal of Orthodontics and Dentofacial Orthopedics* 102: 342–350
- Hoppenreijts T J, Freihofer H P, Stoelinga P J, Tuinzing D B, van't Hof M A 1998 Condylar remodelling and resorption after Le Fort I and bimaxillary osteotomies in patients with anterior open bite. A clinical and radiological study. *International Journal of Oral and Maxillofacial Surgery* 27: 81–91
- Hoppenreijts T J M, Freihofer H P M, Stoelinga P J W, Tuinzing D B, van't Hof M A, van der Linden F P G M, Nottet S J 1997 Skeletal and dento-alveolar stability of Le Fort I intrusion osteotomies and bimaxillary osteotomies in anterior open bite deformities. A retrospective three-centre study. *International Journal of Oral and Maxillofacial Surgery* 26: 161–175
- Huang G J 2002 Long-term stability of anterior open-bite therapy: a review. *Seminars in Orthodontics* 8: 162–172
- Iannetti G, Fadda M T, Marianetti T M, Terenzi V, Cassoni A 2007 Long-term skeletal stability after surgical correction in Class III open-bite patients: a retrospective study on 40 patients treated with mono- or bimaxillary surgery. *Journal of Craniofacial Surgery* 18: 350–354
- Janson G, Valarelli F P, Henriques J F C, de Freitas M R, Cançado R H 2003 Stability of anterior open bite nonextraction treatment in the permanent dentition. *American Journal of Orthodontics and Dentofacial Orthopedics* 124: 265–276
- Kirveskari P 1981 Anterior guidance in somatognathic function. *Proceeding of the Finnish Dental Society* 77: 73–78
- Kravitz N D, Kusnoto B 2007 Posterior impaction with orthodontic miniscrews for openbite closure and improvement of facial profile. *World Journal of Orthodontics* 8: 157–166
- Lopez-Gavito G, Wallen T R, Little R M, Joondeph D R 1985 Anterior open-bite malocclusion: a longitudinal 10-year postretention evaluation of orthodontically treated patients. *American Journal of Orthodontics* 87: 175–186
- Milosevic A, Samuels R H 1998 Functional occlusion after fixed appliance orthodontic treatment: a UK three-centre study. *European Journal of Orthodontics* 20: 561–568

- Milosevic A, Samuels R H 2000 The post-orthodontic prevalence of temporomandibular disorder and functional occlusion contacts in surgical and non-surgical cases. *Journal of Oral Rehabilitation* 27: 142–149
- Park H S, Jang B K, Kyung H M 2005 Maxillary molar intrusion with micro-implant anchorage (MIA). *Australian Orthodontic Journal* 21: 129–135
- Proffit W R, Phillips C 2003 Physiologic responses to treatment and postsurgical stability. In: Proffit W R, White R P Jr., Sarver D M (eds). *Contemporary treatment of dentofacial deformity* Mosby, St. Louis, pp. 646–676
- Proffit W R, Turvey T A, Phillips C 1996 Orthognathic surgery: a hierarchy of stability. *International Journal of Adult Orthodontics and Orthognathic Surgery* 11: 191–204
- Proffit W R, Turvey T A, Phillips C 2007 The hierarchy of stability and predictability in orthognathic surgery with rigid fixation: an update and extension. *Head & Face Medicine* 3: 21–31
- Proffit W R, Bailey L J, Phillips C, Turvey T A 2000 Long-term stability of surgical open-bite correction by Le Fort I osteotomy. *Angle Orthodontist* 70: 112–117
- Pullinger A G, Seligman D A, Gornbein J A 1993 A multiple logistic regression analysis of the risk and relative odds of temporomandibular disorders as a function of common occlusal features. *Journal of Dental Research* 72: 968–979
- Remmers D, Van't Hullenaar R W, Bronkhorst E M, Bergé S J, Katsaros C 2008 Treatment results and long-term stability of anterior open bite malocclusion. *Orthodontics and Craniofacial Research* 11: 32–42
- Reynolds S T, Ellis E 3rd, Carlson D S 1988 Adaptation of the suprahyoid muscle complex to large mandibular advancements. *Journal of Oral and Maxillofacial Surgery* 46: 1077–1085
- Roth R H 1981 Functional occlusion for the orthodontist. *Journal of Clinical Orthodontics* 15: 32–40
- Sassouni V, Nanda S 1964 Analysis of dentofacial vertical proportions. *American Journal of Orthodontics* 50: 801–823
- Sherwood K H, Burch J G, Thompson W J 2002 Closing anterior open bites by intruding molars with titanium miniplate anchorage. *American Journal of Orthodontics and Dentofacial Orthopedics* 122: 593–600
- Subtelny J D, Sakuda M 1964 Open bite: diagnosis and treatment. *American Journal of Orthodontics* 50: 337–358
- Swinnen K *et al.* 2001 Skeletal and dento-alveolar stability after surgical-orthodontic treatment of anterior open bite: a retrospective study. *European Journal of Orthodontics* 23: 547–557
- Umemori M, Sugawara J, Mitani H, Nagasaka H, Kawamura H 1999 Skeletal anchorage system for open-bite correction. *American Journal of Orthodontics and Dentofacial Orthopedics* 115: 166–174
- Xun C, Zeng X, Wang X 2007 Microscrew anchorage in skeletal anterior open-bite treatment. *Angle Orthodontist* 77: 47–56